

# Infected aneurysm of brachial artery after mitral valve infective endocarditis

## *Aneurisma infectado de artéria braquial após endocardite infecciosa de valva mitral*

Heraldo Guedis LOBO FILHO<sup>1</sup>, Eduardo Rebouças CARVALHO<sup>2</sup>, José Glauco LOBO FILHO<sup>3</sup>, Patrícia Leal Dantas LOBO<sup>4</sup>

RBCCV 44205-1257

### *Abstract*

We present hereby a case of pseudoaneurysm of the brachial artery in a patient with infectious endocarditis from *Streptococcus bovis*. A 49-year-old presented with fever, dyspnea and regurgitative murmur in mitral area radiating to the axilla. The echocardiogram showed mitral valve vegetation native. After mitral valve replacement with biological prosthesis implantation, there was a pulsatile mass five cm in the right antecubital fossa. He was diagnosed with pseudoaneurysm of the brachial artery, and surgery was successfully performed. The purpose of this case report is to present an uncommon complication after infective endocarditis.

**Keywords:** Endocarditis. Brachial artery. Pseudoaneurysm.

### *Resumo*

Apresentamos um caso de aneurisma infectado de artéria braquial em paciente com endocardite infecciosa por *Streptococcus bovis*. Homem de 49 anos de idade se apresentou com febre, dispnéia e sopro regurgitativo em foco mitral com irradiação para axila. O ecocardiograma demonstrou vegetação em valva mitral nativa. Após troca valvar mitral com implante de prótese biológica, observou-se massa pulsátil de cinco centímetros de diâmetro em fossa antecubital direita. Foi feito o diagnóstico de aneurisma infectado de artéria braquial, e o tratamento cirúrgico foi realizado com sucesso. O objetivo desse relato de caso é apresentar uma complicação pouco comum após endocardite infecciosa.

**Descritores:** Endocardite. Artéria braquial. Aneurisma infectado.

## INTRODUCTION

The term mycotic aneurysm was first used by William Osler in 1885 to describe a patient who had multiple aneurysms of the aorta, secondary to an infectious process, which he described as malignant mycotic endocarditis [1].

Currently, the tendency is to call it a pseudoaneurysm [2]. It is defined as a localized, irreversible dilatation of an artery by at least 1.5 times its normal diameter, and the disruption of the vascular wall caused by an infection. Usually arises as a result of infection of a previously normal artery or more rarely as a result of secondary infection of a preexisting aneurysm [3].

1. Surgeon General, 3rd year of specialization in Cardiac Surgery.
2. Scholar of the 6th year of medical school - UFC; Trainee of the Heart Institute Dr. Glauco Lobo.
3. PhD in Surgery - UFRJ; Heart Surgeon - UFC, member of the Brazilian Society of Cardiovascular Surgery.
4. Ph.D. in Pharmacology - UFC, Surgeon Dentist.

Correspondence address:  
Heraldo Guedis Lobo Filho  
Rua José Lourenço, 777 – Aldeota – Fortaleza, CE, Brasil – CEP:  
60115-280  
E-mail: heraldolobofilho@hotmail.com

Work performed at the Heart Institute Dr. Glauco Lobo, Hospital São Raimundo.

Article received on January 31<sup>st</sup>, 2009  
Article accepted on July 20<sup>th</sup>, 2009

When associated with acute endocarditis, the pathogenesis is related to the release of septic emboli of cardiac focus, through the bloodstream, lodge in atherosclerotic plaques or vasovasorum, causing heart attacks and inflammation of the vessel wall, with consequent damage layer average. This damage causes the arterial wall, with dilatation and aneurysm formation [4].

The aim of this study is to report the case of a patient after surgery for mitral valve replacement for infective endocarditis, developed a large mycotic aneurysm of the right brachial artery and underwent surgery for resection of the same derivation and brachial-radial graft using saphenous magna successfully.

### CASE REPORT

FJCS patient, 49 years old male, married, was admitted with complaints of daily fever, dyspnea, poor general condition, malaise and weight loss in two months. Seven days before admission she began to present dyspnea on mild exertion and dry cough. There were reports of episodes of melena. Reported a dental ten days before the onset of symptoms. Past medical history of depression. He denied drinking, smoking or intravenous drug use. On examination on admission revealed the following: general state committed to regular, acyanotic, anicteric, febrile, pale, taquisfigmia (regular), tachydyspnea, regurgitative systolic murmur loudest at the apex radiating to axilla, crackles in both lung bases, spleen and liver were palpable, this, four inches below the right costal margin.

The serum tests showed: hemoglobin 7.5 mg / dL (with hypochromic and microcytic), leukocytosis with left shift, creatinine 2.8 mg / dl, urea 100 mg / dl. Chest radiography showed normal cardiac area with signs of pulmonary congestion. Because the diagnosis of infective endocarditis of the mitral valve, blood cultures were taken (being isolated *Streptococcus bovis* sensitive to ceftriaxone) and intravenous antibiotic therapy with ceftriaxone, with cessation of fever after 48 hours of its use. The echocardiogram showed prolapse involving both leaflets of the mitral valve, thickened and calcified leaflets with myxomatous aspect; filament image, mobile, pedunculated, on the face of atrial anterior leaflet, measuring 8x10 mm, compatible with vegetation; image suggestive of perforation in anterior leaflet, and two jets reflux severe mitral regurgitation.

Due to the association of infective endocarditis by *Streptococcus bovis* and the presence of malignant or premalignant colon, colonoscopy was performed, which showed a colonic polyp benign aspect, and subsequently resected endoscopically identified by histopathology, colonic polyp as hyperplastic.

The patient underwent intravenous antibiotic for 21

days, due to severe mitral regurgitation and the occurrence of new peaks of fever, heart surgery was indicated. We performed mitral valve replacement with porcine bioprosthetic implant. The intraoperative and postoperative period progressed uneventfully. The patient, after surgery, received more than 14 days of antibiotic therapy.

Before hospital discharge, we noticed the emergence of a mass of 1 cm in diameter in the right antecubital fossa, assigned as the case of a subcutaneous nodule. Outpatients, 45 days after surgery, the patient presented with increased mass quoted, which now measure about 5 cm in diameter, being perceived pulsatility and lateral expansion. Doppler ultrasound was requested which showed in the right brachial artery, the presence of aneurysm, measuring approximately 4 cm in diameter, before the bifurcation and incorporating the same (Figure 1). In this examination, we observed that the radial artery showed monophasic flow and hypokinetic (systolic peak velocity - PSV: 10.6 cm/s), suggesting severe proximal stenosis, probably due to compression by the aneurysm. The ulnar artery were patent, with regular caliber throughout its course, with antegrade flow, laminar, normocinético, normotensive and phase (PSV: 49.7 cm/s).

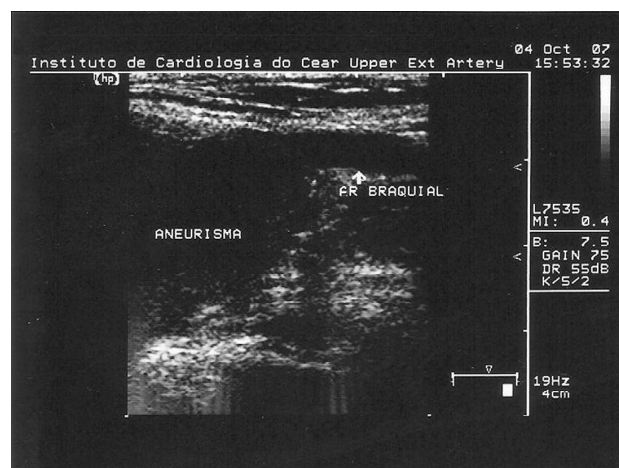


Fig. 1 - Ultrasound showing the relationship of the aneurysm with the right brachial artery

The patient underwent aneurysm resection and interposition reverse saphenous vein graft in brachial-radial location, with ligation of the ulnar branch, since there was a significant retrograde flow through this branch (Figures 2 and 3). The postoperative course was uneventful. Echo-Doppler ultrasound, after two weeks, demonstrated patency of the graft with antegrade flow in radial and ulnar

arteries. On histopathology, it was observed under the microscope: artery showing loss of elastic fibers of the middle layer associated with the deposition of mucoid substance; extensive hyalinization; adventitia with mild infiltration linfomolecular; vasovasorum thickening. Conclusion: Transformation of mucoid middle layer of the brachial artery aneurysm.

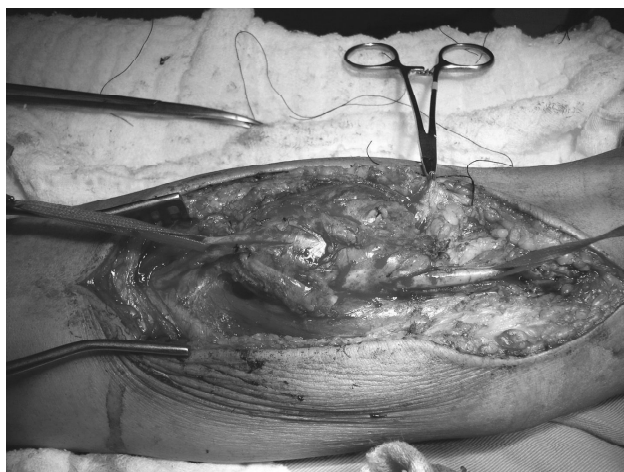

Fig. 2 - Image surgical aneurysm right brachial artery, compromising its bifurcation. It is heart repaired with tape on the right brachial artery proximal to the aneurysmal involvement



Fig. 3 - Final aspect after aneurysm resection and interposition reverse saphenous vein graft in brachial-radial location

## DISCUSSION

Over 80% of cases of infected aneurysms have intracranial, intrathoracic or intra-abdominal. The involvement of the upper extremities is seen in about 10% of cases, the brachial artery being the most affected in this segment. Infected aneurysms of the brachial artery have been reported most frequently in association with intravenous drug abuse, invasive catheterization procedures or prosthetic valve endocarditis [2].

A recent article in the literature review found 27 articles with 52 reported cases of infected aneurysms of the brachial artery. There was a greater predilection for males. The mean age at presentation of disease was 41.4 years. In most cases, the aneurysms were secondary to injection drug use. The diameters ranged from 1 to 8 cm. In the cases studied, the most common organism was *Staphylococcus aureus*.

When associated with acute endocarditis, the pathogenesis is related to the release of septic emboli of cardiac focus that enter the bloodstream and become lodged in atherosclerotic plaques or vasovasorum, causing heart attacks and inflammation of the vessel wall, with subsequent necrosis of the middle layer. Before 1965, infectious endocarditis was associated with roughly a third of mycotic aneurysms. After 1965, probably due to the large scale introduction of antibiotics, this association has been seen in only 10% of cases. The arterial trauma has become the most frequent cause, due to the increase in hemodynamic procedures and injecting drug users [4].

The growth of these aneurysms is rapid. In studies of the thoracic aorta, it was shown that such aneurysms present evolution of several centimeters per month, whereas in non-infected aneurysm progression is estimated from 0.3 to 0.6 cm per year. If left untreated, often follow a rapid course, with high mortality [3].

Regarding the historical treatment of pseudoaneurysm of the brachial artery, we found that in 1948, Hurwitz and colleagues reported the case of a patient 20 years after clinical cure of an infectious endocarditis from *Streptococcus pneumoniae*, underwent surgery that involved ligation and excision of the aneurysm. In 1958, Sullivan and Mangiardi [5] described the case of a patient treated with penicillin because of aortic valve endocarditis caused by *Streptococcus viridans*. Nine years later, he presented with a pulsatile palpable mass and in left antecubital fossa. He then underwent excision and end anastomosis of the brachial artery and radial artery ligation distal ulnar.

Controversies exist about the best surgical management of these aneurysms. Accepted strategies include: 1) binding of the affected arterial segment and debridement of all necrotic and infected tissue, 2) connection and debridement followed by arterial revascularization in elective surgical

time of 2 and 3) simultaneous connection, immediate debridement and revascularization. Due to the rarity of this condition, the results of all series of studies are based on small numbers of patients and may significantly differ for various segments of aneurysms involving one or more arteries [6].

Endovascular techniques have also been reported, but currently is recommended only in emergencies or as a bridge to definitive treatment [6].

#### REFERENCES

1. Osler EA. The Gulstonian lectures on malignant endocarditis. *Brit M J*. 1885;1:469.
2. Leon LR, Psalms SB, Labropoulos N, Mills JL. Infected upper extremity aneurysms: a review. *Eur J Vasc Endovasc Surg*. 2008;35(3):320-31.
3. Shaikholeslami R, Tomlinson CW, Teoh KH, Molot MJ, Duke RJ. Mycotic aneurysm complicating staphylococcal endocarditis. *Can J Cardiol*. 1999;15(2):217-22.
4. How P, Sikkell MB, Shalhoub J, Law NW. Mycotic aneurysm of the brachial artery secondary to hospital-acquired methicillin-resistant *Staphylococcus epidermidis* in a complicated case of infective endocarditis. *Ann Vasc Surg*. 2006;20(5):684-6.
5. Sullivan JJ Jr, Mangiardi JL. Surgical management of mycotic aneurysms. *Ann Surg*. 1958;148(1):119-24.
6. Benjamin ME, Cohn EJ Jr, Purtill WA, Hanna DJ, Lilly MP, Flinn WR. Arterial reconstruction with deep leg veins for the treatment of mycotic aneurysms. *J Vasc Surg*. 1999;30(6):1004-15.